

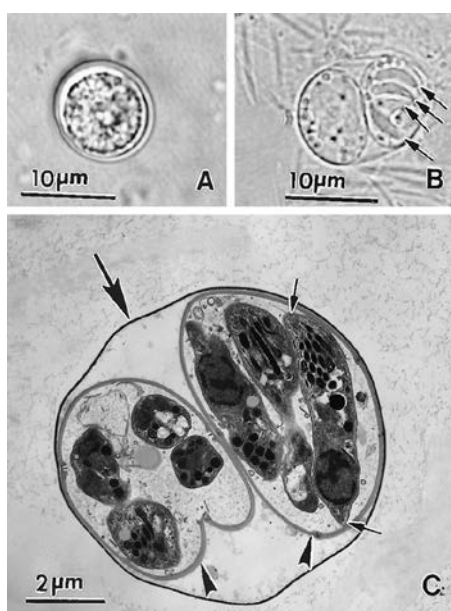
# TOXOPLASMOSIS

In a world of ubiquitous parasites, *T. gondii*, is 'Mr Ubiquitous'. This obligate intracellular protist is *everywhere* — resilient **oocysts** in soil (courtesy of felid faeces) and **tissue cysts** in almost all type of warm-blooded vertebrate (livestock etc.). "Everywhere" includes 1 in 3 humans. And no vector in site.

All stages are infectious, but infection too often is subclinical or mild flu- or mono-like — the host immune response suppresses but rarely, if ever, kills *T. gondii*, which prevents phago-lysosomal fusion within macrophages. It then enters dormancy, particularly in muscle cells and the central nervous system (especially the eye), but can infect any cell type. Dormant, that is, if the host is immunocompetent.



Steak tartare is popular in France, and so too is toxoplasmosis.



*T. gondii* oocysts are excreted in cat poo, usually early on in the animal's life, before immunity kicks in.

## Two groups to worry about

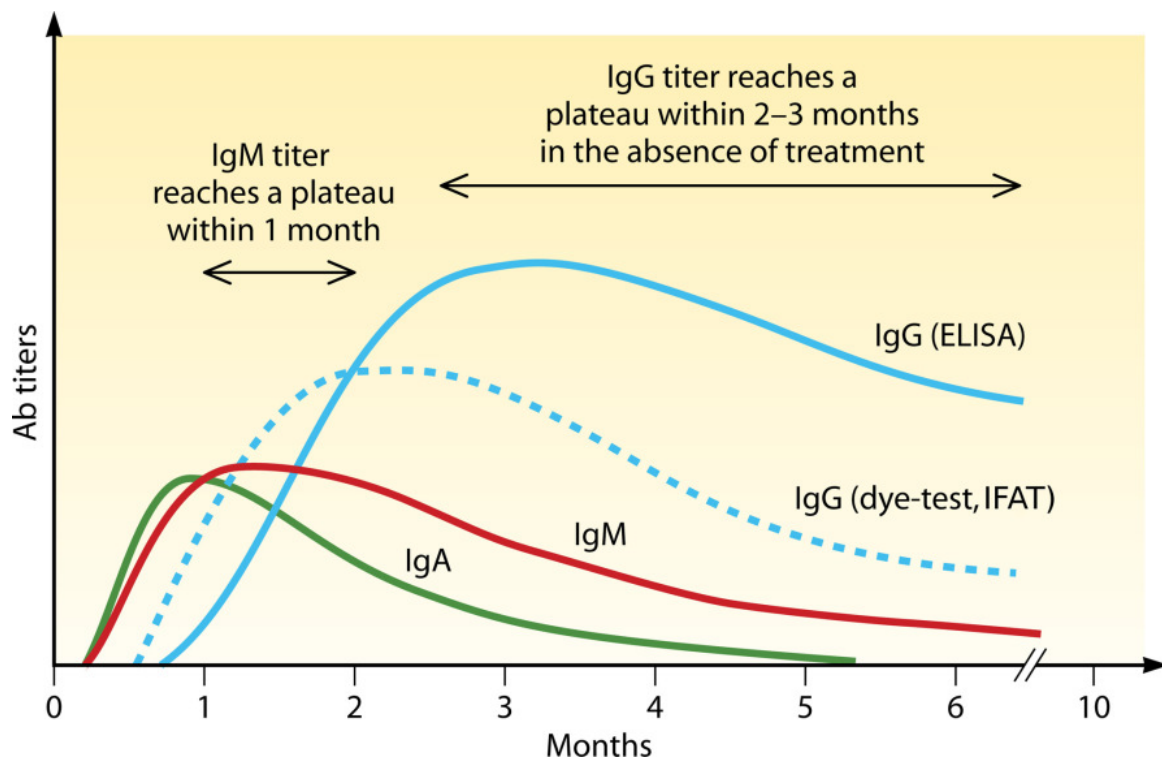
1. Pregnant → foetal toxoplasmosis (one of the TORCH infections)
2. Immunosuppressed, especially HIV → CNS toxoplasmosis (an AIDS-defining illness)

Treatment needs to be considered in each of pregnant mothers, neonates, and the immunosuppressed. Treating pregnant mothers reduces the risk of congenital toxoplasmosis in the baby. Apparently normal children need follow-up: clinical manifestation often present later in childhood, and often as visual impairment. Manifestations in a HIV patient is indication for treatment as well as life-long chemoprophylaxis.

## Clinical

### Pregnant

- Primary infection often mild and flu-like, but must be considered in those at high risk (e.g. clean cat litter)
- Cook meat well (most parasites are also killed by freezing), wash vegetables
- Treatment is usually indicated to reduce/prevent foetal exposure
  - Dx: Serology → Amniocentesis + PCR
  - Rx: Spiramycin ± Sulfadiazine (**pyrimethamine is C/I in 1st & 2nd trimesters**)
  - Px: Good for mum (for foetus depends on stage of pregnancy)

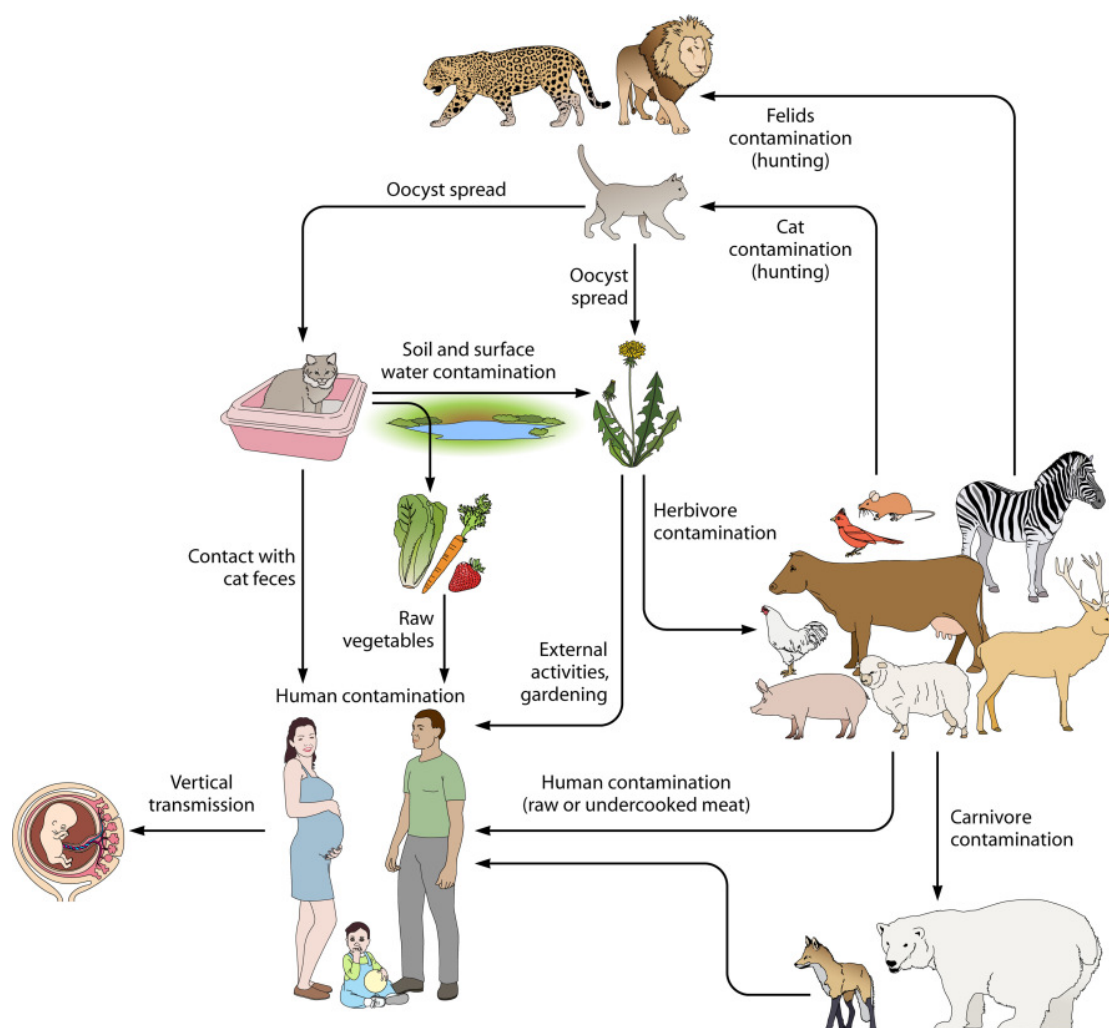


### Neonate/Child

- manifests as anything from mild to devastating (hydrocephalus, chorioretinitis, intracerebral calcifications = classic triad)
- later visual problems in childhood (through to adolescence) very common but often missed
  - Dx: Fundoscopy ± slit-lamp; Serology ± other (e.g. CSF); CT/MRI Brain
  - Rx: Pyrimethamine + Sulfadiazine + Folinic acid (for up to a year)
  - Px: Monitor throughout childhood

Immunosuppressed (e.g. HIV/AIDS)

- chorioretinitis — *T. gondii* most common cause of a posterior uveitis (harbinger of CNS toxo in 30%)
- CNS toxo → life-long chemoprophylaxis
- pneumonitis
- myocarditis
  - Dx: Fundoscopy ± slit-lamp; CT/MRI Brain; Bronchoalveolar lavage/CSF/tissue biopsy → ELISA or PCR
  - Rx: Pyrimethamine + Sulfadiazine + Folinic acid
  - Px: Life-long chemoprophylaxis



## References:

- Robert-Gangneux, Florence and Dardéc, Marie-Laure. [Epidemiology of and Diagnostic Strategies for Toxoplasmosis](#). *Clinical Microbiology Reviews*. April 2012 Volume 25 Number 2.
- Hill DE, Chirukandotha S, Dubey JP. [Biology and epidemiology of Toxoplasma gondii in man and animals](#). *Animal Health Research Reviews*. Volume 6: Issue 01. June 2005, pp 41-6
- [Congenital Toxoplasmosis](#), Mary T. Caserta, MD. Merck Manual Professional Version.
- Dubey JP, Lindsay DS, and Speer CA. [Structures of Toxoplasma gondii: Tachyzoites, Bradyzoites, and Sporozoites and Biology and Development of Tissue Cysts](#). *Clinical Microbiology Reviews*. **April 1998** vol. 11 no. 2 **267-299**